PAINFUL SHOULDER SYNDROME IN THERMAL AND SONOGRAM IMAGING

Gabrhel J., Popracová Z., Tauchmannová H.

Trenčín, Trnava, Pieštany

XV Congress of the European Association of Thermology
2ND - 3RD september 2021, **Wroclaw**

INTRODUCTION

- The shoulder joint is the joint with the greatest range of motion thanks to its anatomical structure and the loose joint capsule.
- The loose articular capsule creates several recesses in which the articular fluid can accumulate, or blood in case of an injury, or even a corpus liberum.
- The stability of the joint and the reinforcement of the shoulder girdle are ensured by ligaments.
- The joint function is made possible by 16 muscles that are attached into the HSC joint area or other structures of the shoulder girdle.
- Smooth movement during muscle activity is supported by 16 bursas.
- In places where there occurs a friction of muscles against firm structures and among individual muscles against one another, a specially structured type of interstitial tissue ensures smooth movement.

ARTICULAR RECESSES AND BURSA SUBACROMIOSUBDELTOIDEA, BURSAE IN THE ANTERIOR PART OF SHOULDERBURSAE IN THE POSTERIOR PART OF SHOULDER,

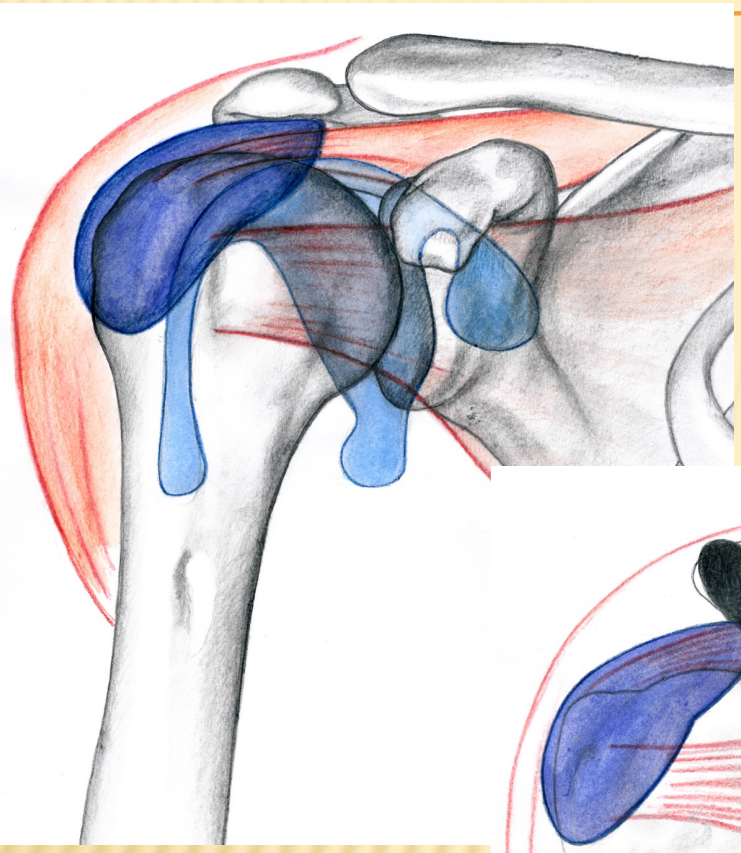

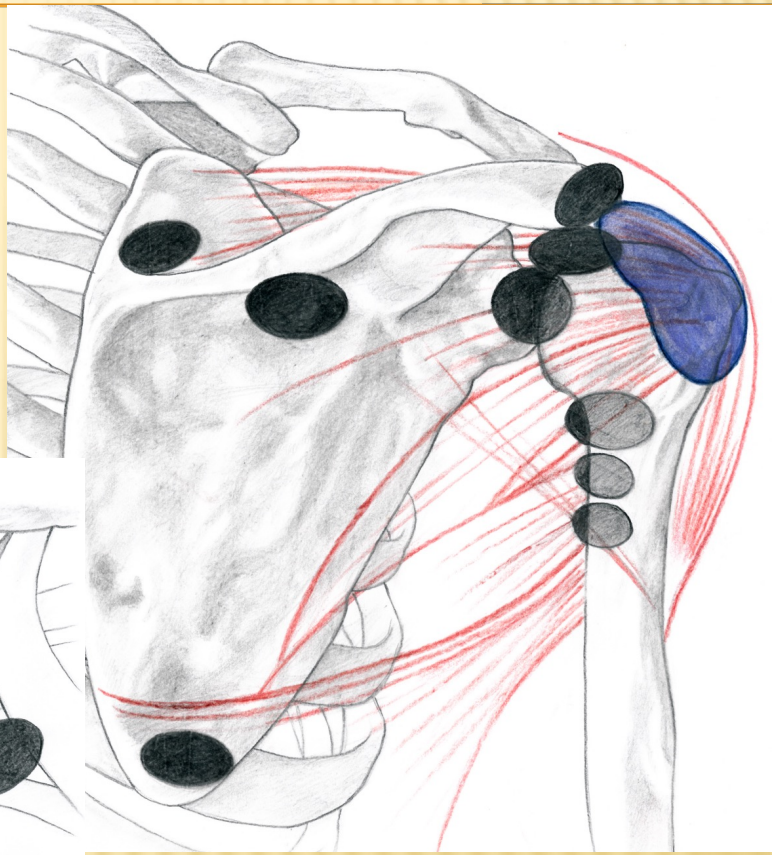

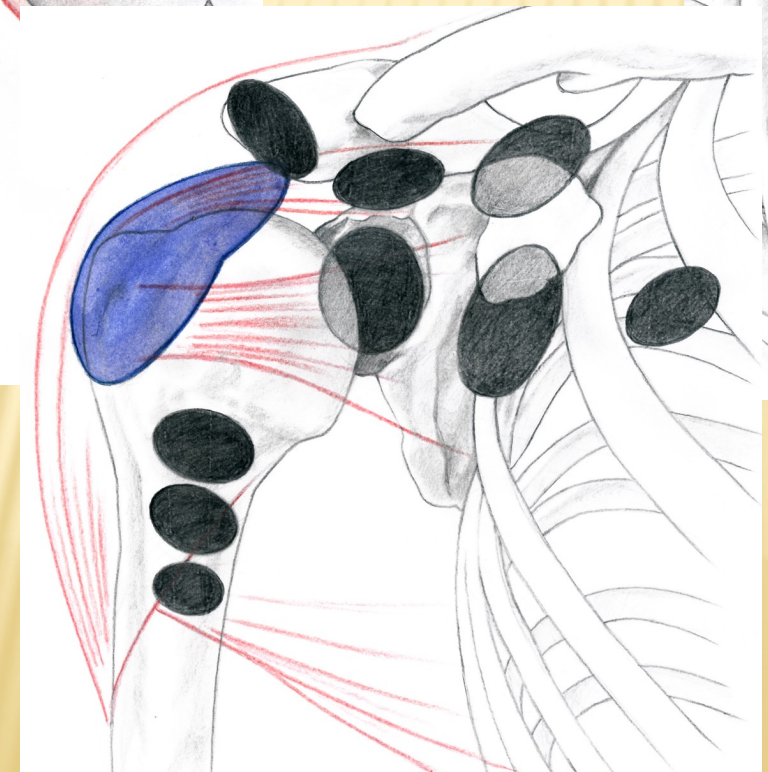

PAIN LOCALIZATION BY THERMOGRAPHY AND SONOGRAPHY

- In any of the described structures, a pain generator may occur following an injury or disease.
- At the site of the pain generator, chemical mediators are released that are detected by different types of nociceptors and subsequently activate nociception pathways.
- There are several basic types of pain according to the type of chemical mediator released.
- It is assumed that different pain types are associated with specific skin temperature distributions.
- **Local inflammatory processes** lead to nociceptive pain, and dependent on the severity of the inflammation to **increased skin temperature** over the painful area.
- Pain may also result in a disturbed balance within the autonomous nervous system. **Sympathetically maintained pain** is defined as pain that is maintained by sympathetic efferent activity or neurochemical or circulating catecholamine action. Affected regions often present with **low skin temperature.**
- However, thermography is a pathophysiological method. It fails to accurately identify the anatomical structures where activated nociceptors are located.
- For these purposes we must use structural imaging methods such as X-ray, MRI, CT, or sonogram. Over the last decade, the quality of ultrasonographic imaging has enormously improved the diagnosis of the musculoskeletal system. It is now possible to display deep-lying structures. The sonographic image is more contrasting and we can better differentiate the examined structures.

OBJECTIVE AND METHOD

OBJECTIVE

- The aim of this study was to classify shoulder pain by thermographic findings.
- Providing the diagnostic properties of thermal imaging, in relation to the morphological findings recorded by sonography.

METHOD

- Our study is a retrospective study in which, out of the total number of patients admitted to our workplace for shoulder pains between January 2010 and December 2019, we only selected those who had a positive sonographic finding and underwent a thermal imaging examination as well.
- All patients went through the physical examination, which include inspection with a particular focus on abnormal vascular findings and superficial skin lesions. Palpation of the shoulder included testing for tenderness of insertions of ligaments and tendons, and assessment of swelling. Functional tests were performed including range of motion, assessment of joint play, joint stability and joint stiffness. Muscle tone and muscle strength were also tested.

- For thermal imaging, we used the Fluke infrared camera Ti32, equipped with a 320 x 240 focal plane array, uncooled microbolometer with thermal sensitivity (NETD) 0.05 °C at 30 °C target temperature.
- The patient was equilibrated in a darkened room at 25° ± 1.0°C for 20 minutes half naked. In addition to the standard positions given by the Glamorgan Protocol, we also used an additional projection – a horizontal one with a 90° forward bend – to record the AC articulation.
- The basic criterion for evaluating the thermographic image of the examined area is the description of temperature deviations from the normal temperature pattern. In temperature active findings, we evaluate the total temperature parameters – Tmax., Tmed., and Tmin. We compare them with temperature parameters in the contralateral symmetrical region (if the contralateral temperature pattern is normal) or to the suroudings. In the area of interest we evaluate both hyperthermia and hypothermia. Thermal findings with Tdif. ≥ ± 0.5°C are considered positive.
- We use an Esaote MyLabSeven ultrasound device with a 5-12 MHz linear probe to perform the sonographic examination. We do not focus exclusively on the pain area; but rather are examining the entire shoulder in each patient. Dynamic tests are included in the sonographic evaluation, when necessary.

RESULTS

- The total number of patients selected was 332. Of these, 191 were men, and 141 women. All patients were aged between 3 and 91 years, with the average of 49,4 years.
- In some cases the examinations were completed by use of other imaging methods. 76 of them were also X-ray screened and 57 had an MRI or CT scans done. Biochemical examinations were performed as well if required for definite diagnostic decisions.
- In skin temperature distribution only 57% of the 332 patients with sonographic abnormalities showed a disturbed temperature distribution. 151 patients presented with hyperthermia in the painful shoulder region, while 40 patients showed low temperatures over the symptomatic shoulder. There were 141 patients whose thermal pattern in the painful shoulder region was similar to that of the unaffected side.

- Combining thermal and physical examination findings has better diagnostic accuracy than just physical examination or thermal findings alone.
- Since only patients with abnormal sonographic findings were included in this evaluation, all patients presented with at least one pathological finding in sonography resulting in a total of 492 findings in 332 patients.
- Tendon pathologies were the most frequent observations, followed by joint and bursae pathologies. The ratio tendon to joint pathologies to bursa affections was similar in normal, hyper- or hypothermic thermal patterns.
- Examples of hyperthermic, hypothermic, and normothermic temperature patterns and their corresponding sonographic findings are provided.

TMV findings - ↑temperature activity

Patient with right shoulder pain lasting 5 years, SONO: AC joint cyst formation, a larger calcification in tendon m. supraspinatus. MRI: arthritic changes in the AC joint, a calcification in the place of the m. supraspinatus attaching.

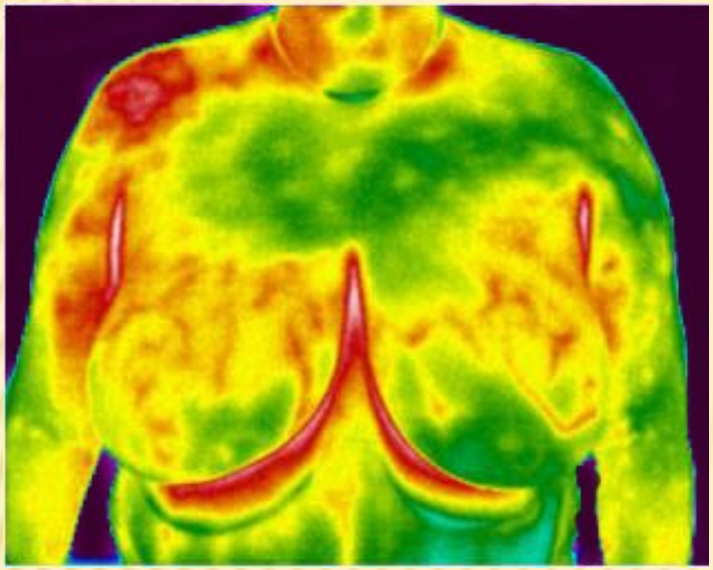

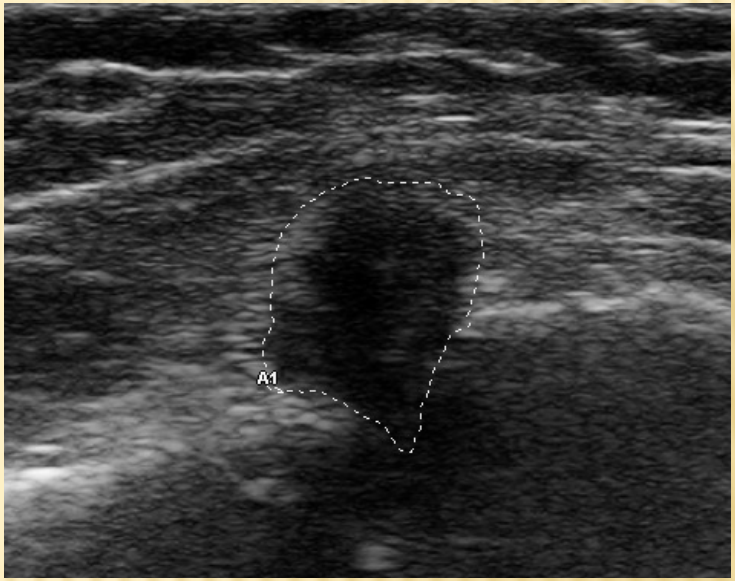

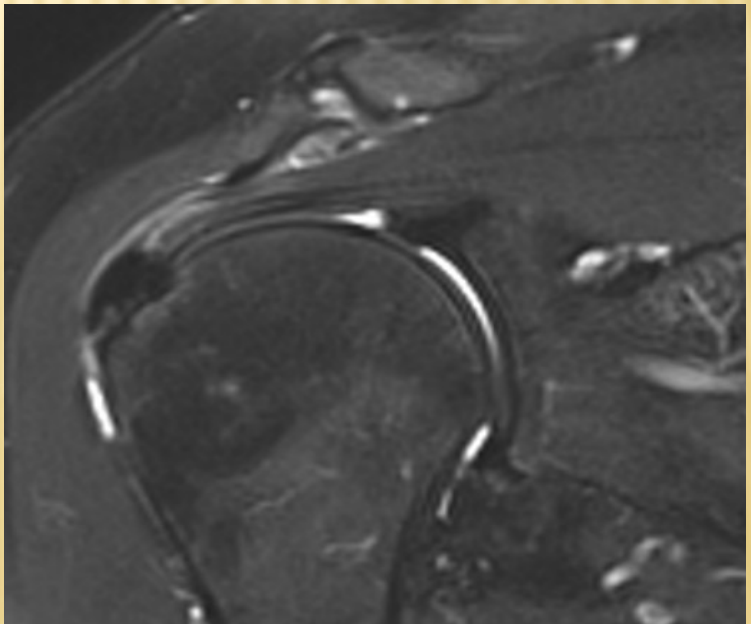

Patient with intramedullary osteosynthesis of fractura comminutiva of the collum chirurgicum humeri on the left side SONO: protruding screws in the lateral part of the head of the humerus. CT: 1 screw is questionable according to the trauma surgeon; he recommends undergoing arthroscopic revision subacromial decompression.

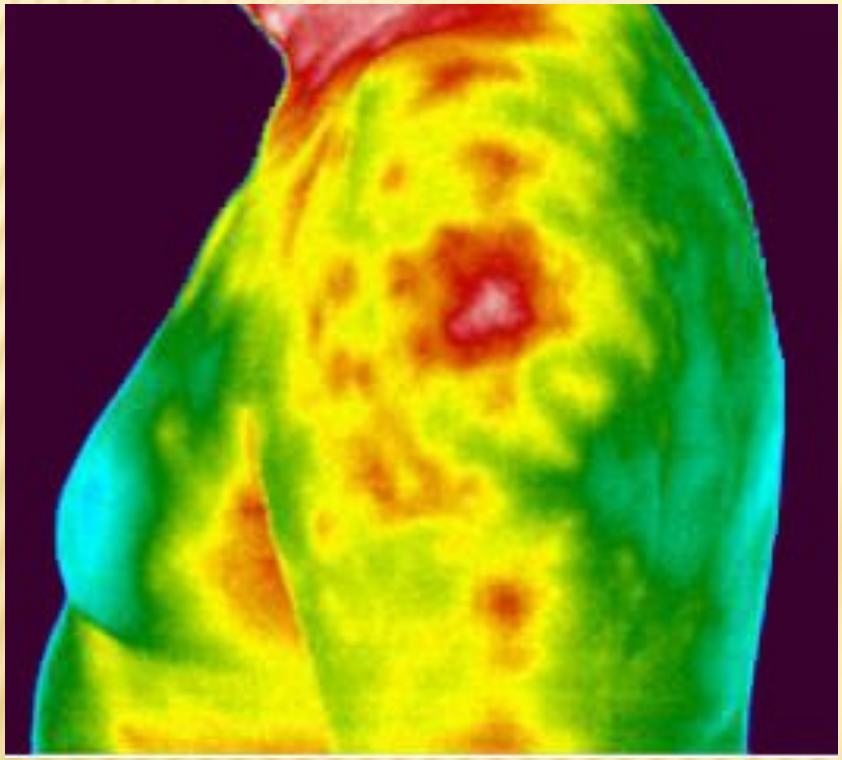

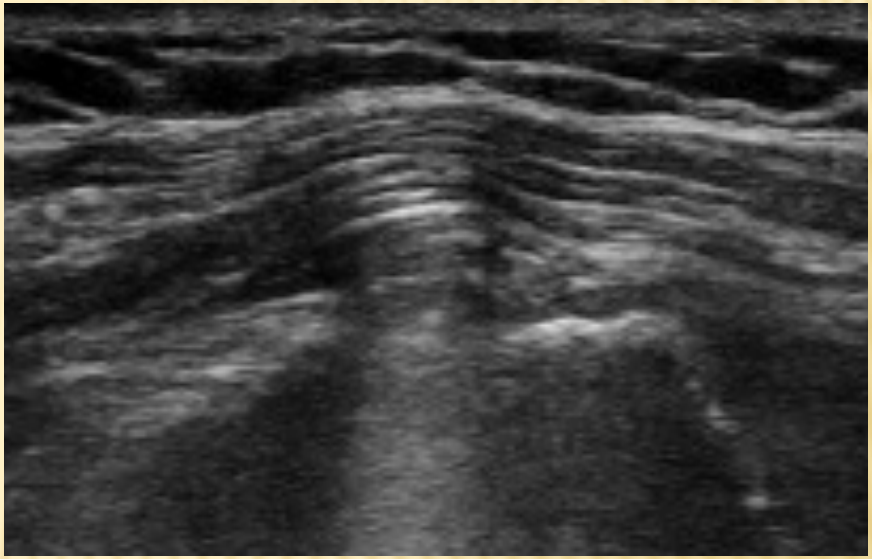

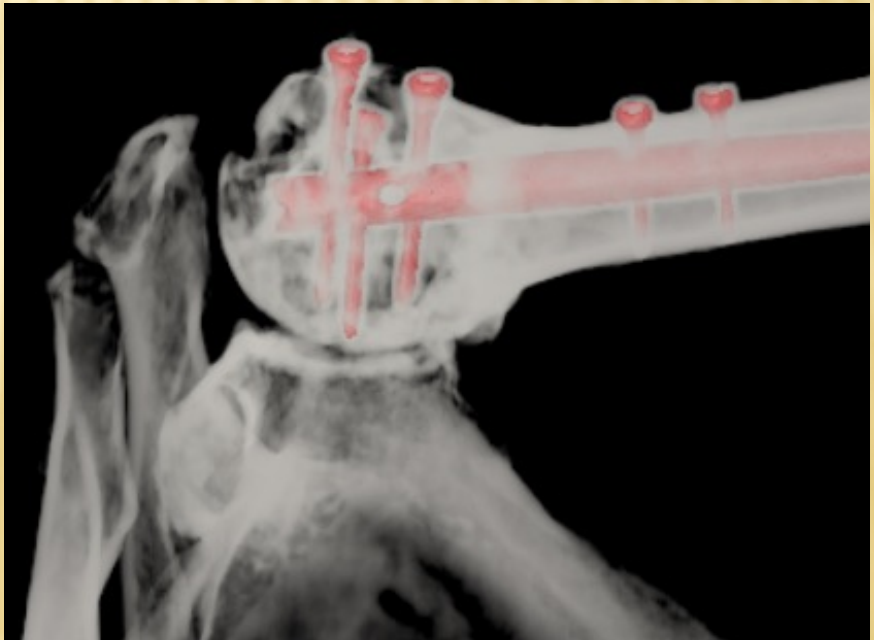

TMV findings - ↓ temperature activity

Patient with left shoulder pain for over a year, elevated uric acid levels. Sono: chondrodegenerative changes of the HSC joint. MRI: rough degenerative HSC changes.

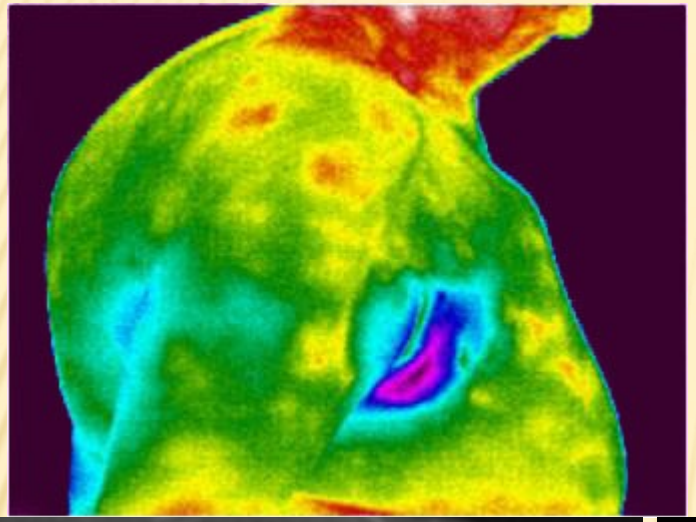

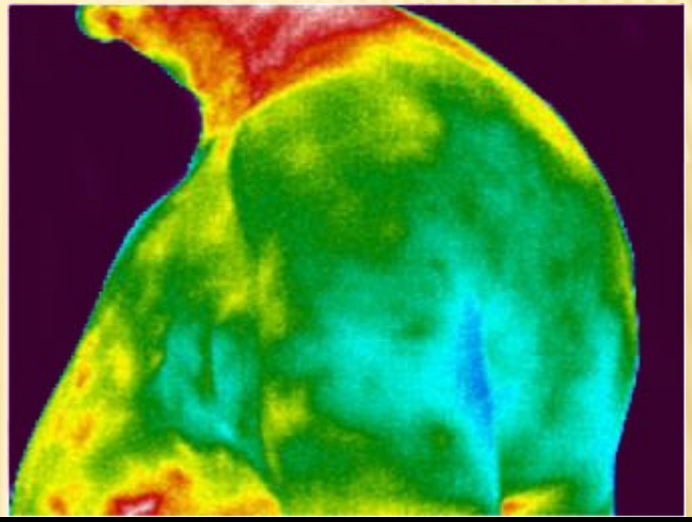

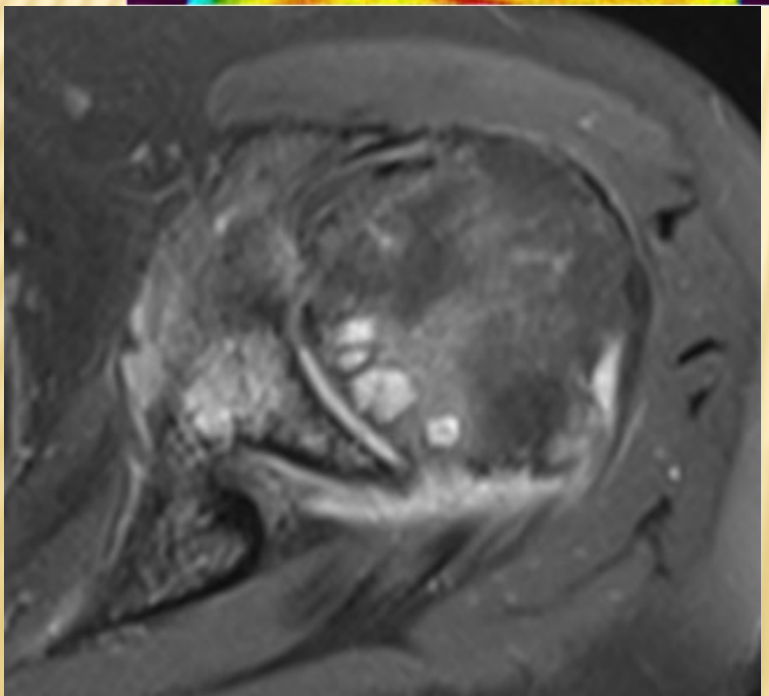

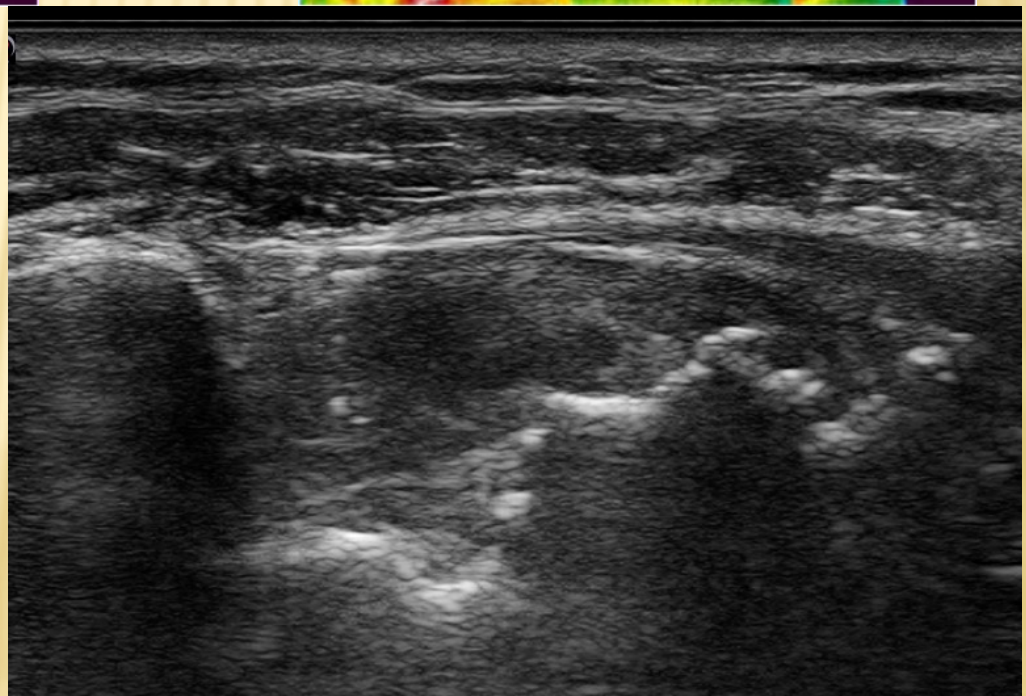

Patient with pain of right shoulder. SONO: chondrodegenerative changes of the humerus head, calcifications in m. supraspinatus, a bursa below lig. coracoacromiale.

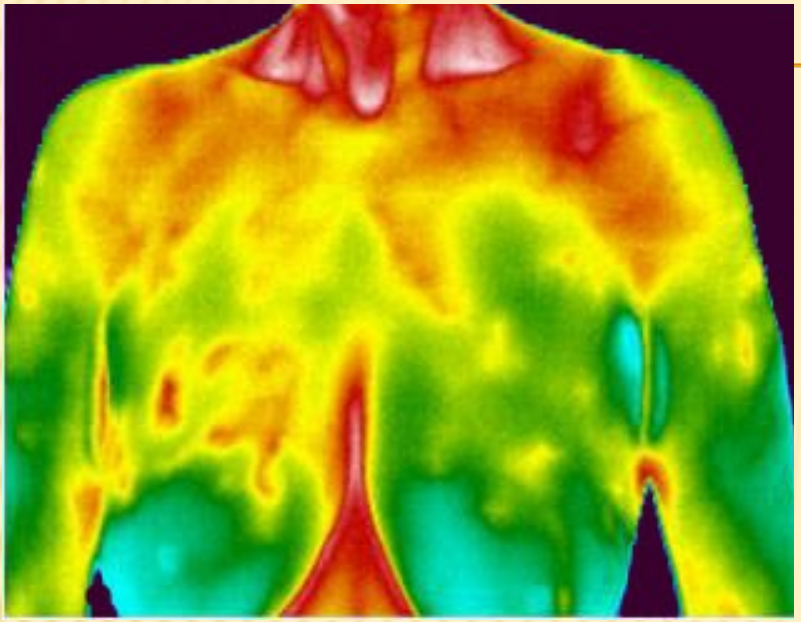

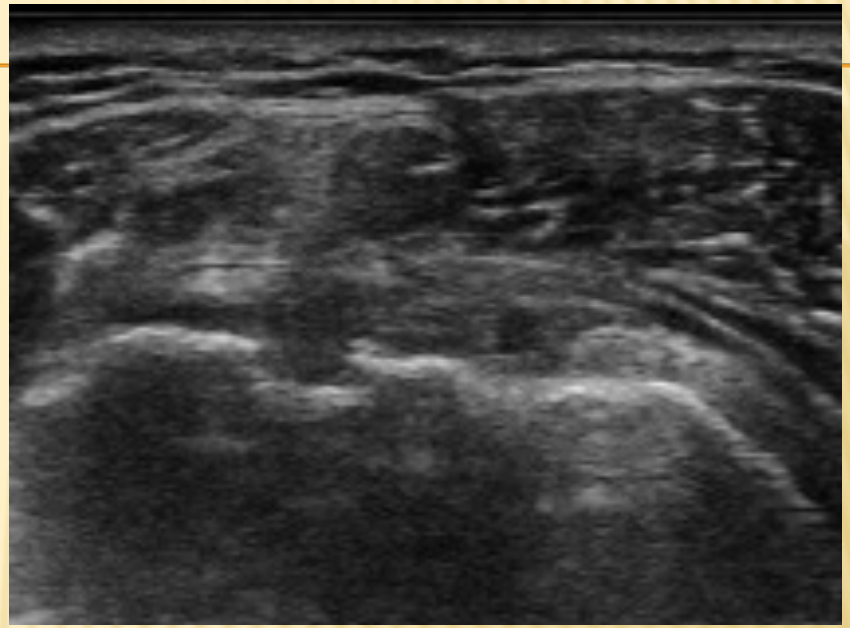

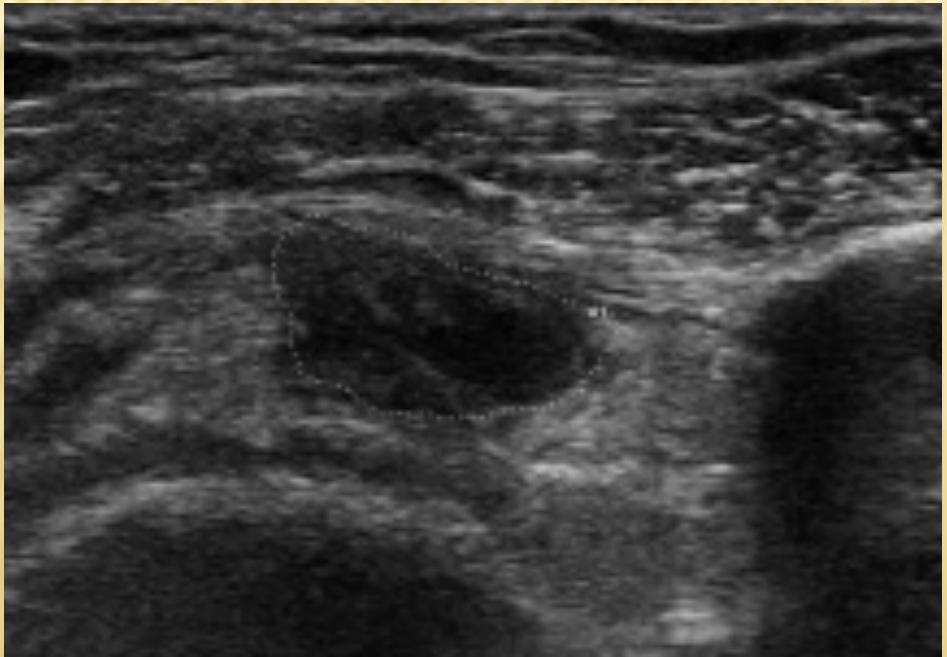

TMV findings - normal temperature pattern

Patient with left shoulder pain after a fall 6 weeks ago. Sono: ruptura partialis m. supraspinati l.sin. ruptura partialis tendinis capiti longi m. bicipitis brachii.

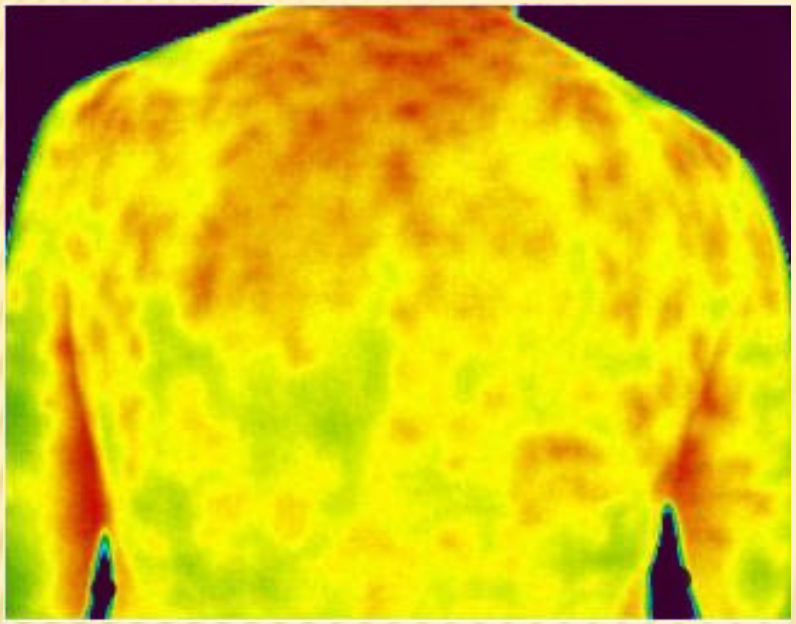

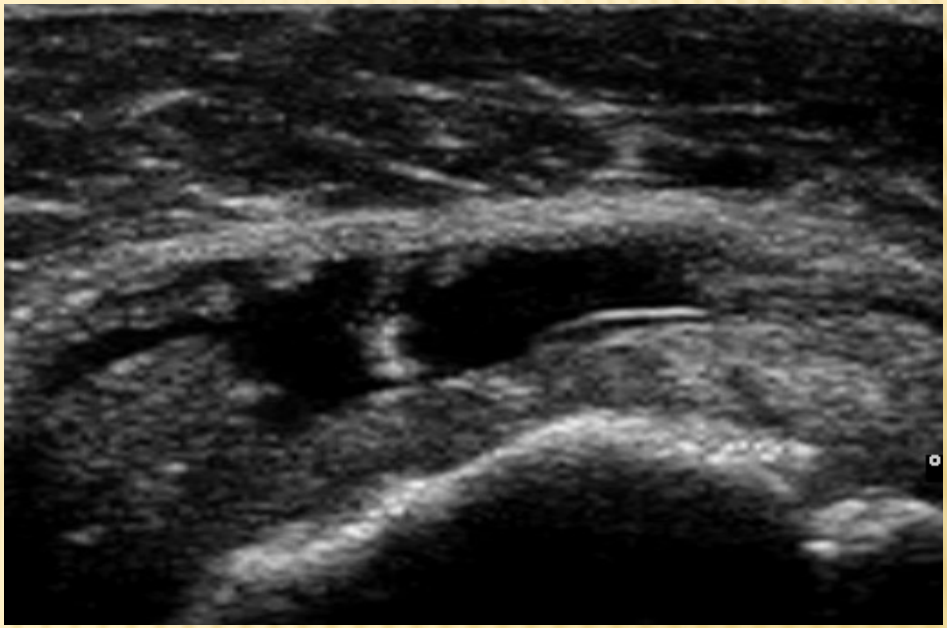

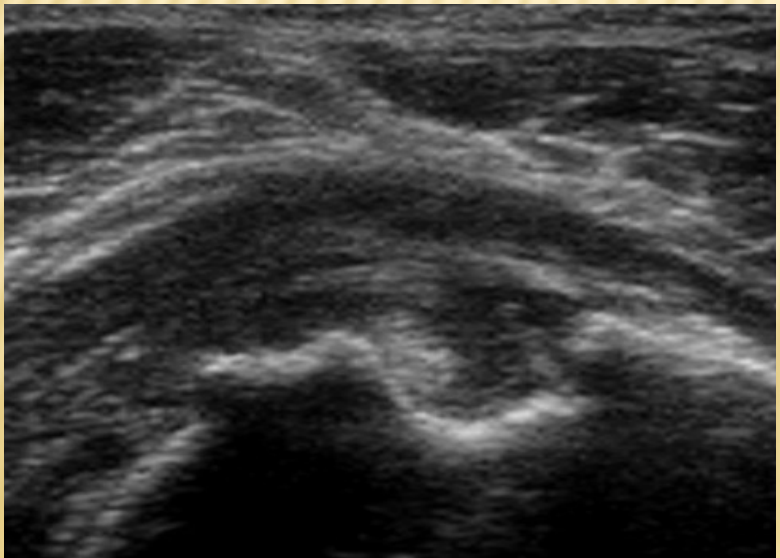

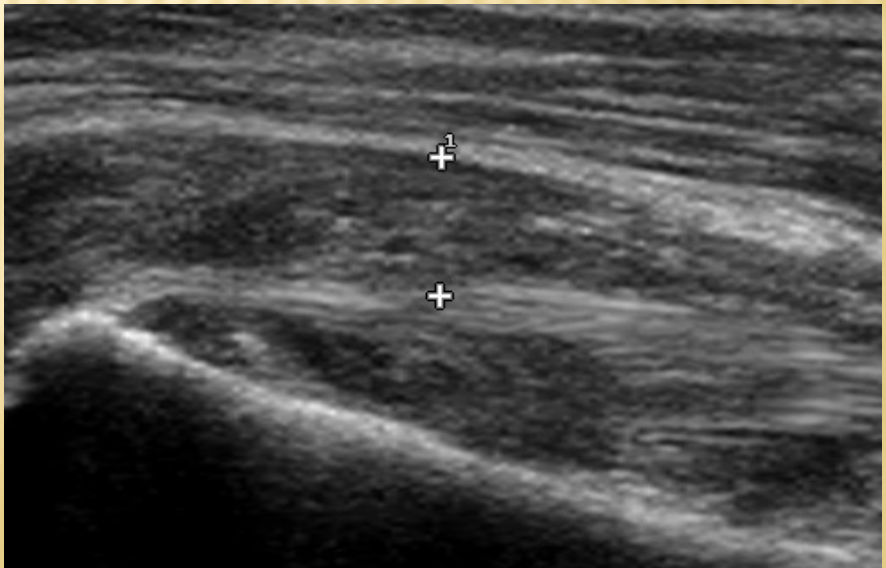

Patient with pain and limited movement of the right shoulder after a fall. Sono: chondrodegenerative and osteoproductive changes, filling in the back of the HSC joint MRI: we see the same findings.

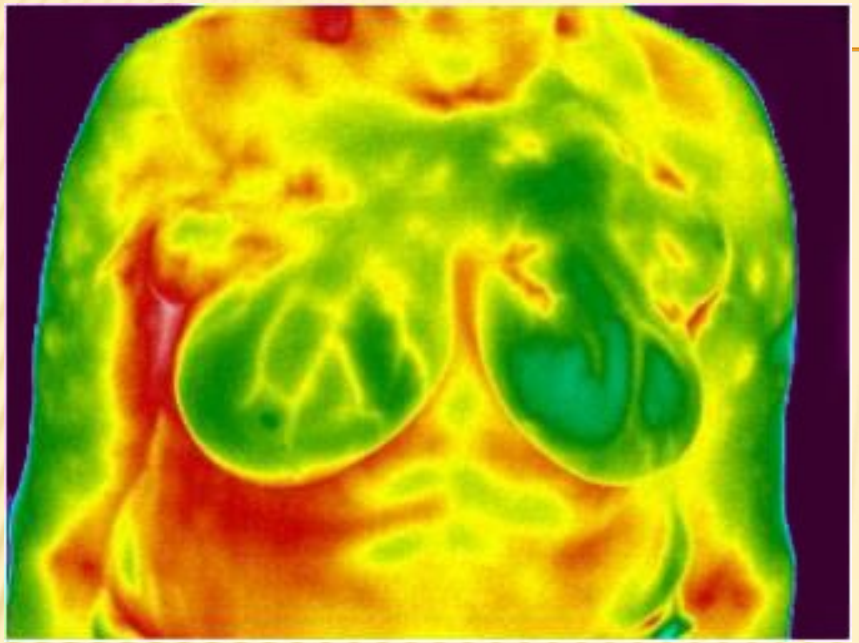

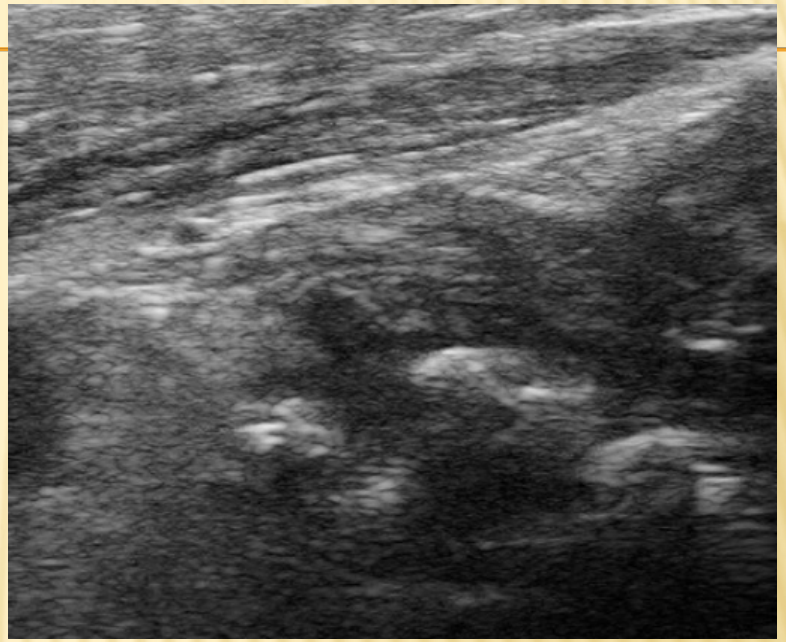

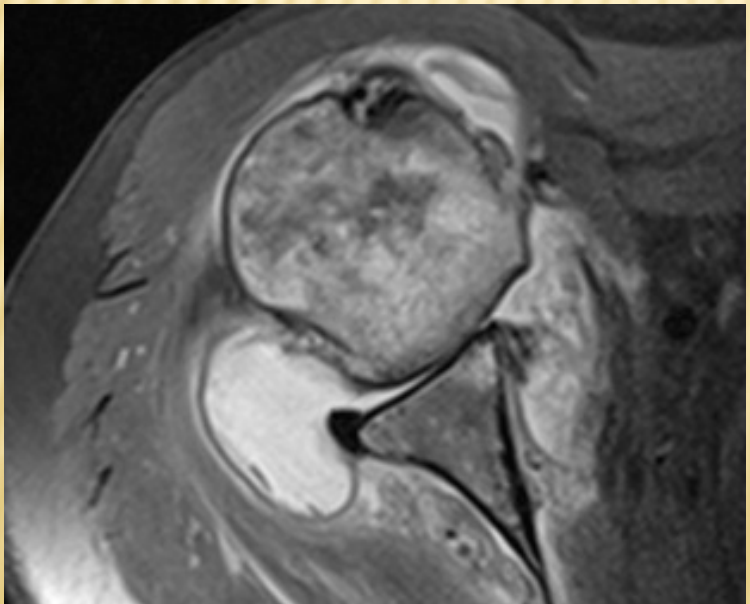

CONCLUSION

- Infrared thermal imaging records the temperature distribution on the surface of the shoulder.
- It provides cues to the pathophysiological processes involved in various pain syndromes.
- The sonographic image fosters easy differentiation of the examined structures.
- The allocation to different pain classes based on thermographic and sonographic findings seems to provide a clinical pathway for the selection of treatment with high probability of success.